

# A PATIENT WITH MENINGEAL MELANOMATOSIS TREATED FOR PERIODONTAL DISEASE WITH A BONE REGENERATION PROCEDURE AND DENTAL IMPLANTS: CLINICAL AND BEHAVIORAL MANAGEMENT TO SUPPORT MEDICAL COMPLIANCE

R. TIZZONI<sup>1</sup>, L. VENERONI<sup>2</sup>, C.A. CLERICI<sup>3</sup>

<sup>1</sup>Private practice, Milan, Italy; <sup>2</sup>Department of Pathophysiology and Transplantation - University of Milan, Milan, Italy; <sup>3</sup>Specialist in Clinical Psychology, Department of Pathophysiology and Transplantation - University of Milan, Milan, Italy

## SUMMARY

**Background.** During the last three decades dental implants have become increasingly used in partially edentulous periodontally compromised patients. The type of bacteria in the peri-implant sulcus is influenced by the periodontal bacteria present on the surfaces of the remaining teeth. Peri-implant sulci of partially edentulous individuals harbour more motile rods and spirochetes than those of fully edentulous individuals. If Peri-implantitis arises, it may lead to implant failure. This complication occurs more frequently in patients with poor oral hygiene. This is a site-specific bacterial infection similar to that caused by periodontal bacteria around teeth and it should be prevented.

**Aim.** This study was conducted to radiographically evaluate hard tissue response around 6 implants, over a 2-year period, in a previously surgically treated patient affected by severe chronic periodontitis. Psychological considerations and behavioral management of the patient are described.

**Materials and methods.** A complex implant-perio-prosthetic case of a 54-year-old man affected by meningeal melanomatosis with a history of generalized severe chronic periodontitis was recruited. A comprehensive periodontal examination around teeth was accomplished before periodontal and implant treatment. After diagnostic work-up, compromised teeth from 1.3 to 2.3 and from 3.2 to 4.2 were extracted. Tooth 1.7 was also extracted. Afterwards fixed provisional restoration rehabilitated all the natural dentition and the missing teeth. Endodontic therapies were conducted on all the teeth due to high dentinal sensitivity and pre-prosthetic crown reconstructions performed. Periodontal surgery with modified Widman flaps were then accomplished on all the teeth. Three months later four maxillary implants in position 1.3, 1.1, 2.1, 2.3 and two mandibular implants in position 4.2, 3.2 were inserted. During mandibular implants positioning, the mental mussels were isolated and detached to achieve proper guided bone regeneration.

During implant surgery, due to systemic conditions concern, the patient underwent intravenous sedation. Five months later the implants and the teeth were rehabilitated with fixed metal-ceramic bridges. Regarding the upper prosthetic rehabilitation, the incisors marginal edges were kept vertical to the nasal spine, due to lack of previous reference points.

According to the reference points previously determined, the difference in bone level between radiographs taken at implants insertion and at the maintenance appointments was calculated.

**Results.** The health of the periodontally treated teeth resulted greatly enhanced. The mean alveolar bone loss was 0,30 mm after a 2-year observation period.

**Conclusions.** The control of the periodontal disease before implant insertion in patients with severe chronic periodontitis is of paramount importance, as well as a regular maintenance program is essential for the health of the periodontal and peri-implant tissues. The management of patients with complex needs requires a multidisciplinary team designed to meet all the patient's needs on various levels.

**Key words:** dental implants, bacterial colonization, bone loss, periodontally compromised patients, patient compliance.

## Introduction

In the last three decades, increasing numbers of partially edentulous patients with periodontal disease have been prosthetically rehabilitated with implant-supported restorations (1), but whether the long-term survival rates of dental implants installed in such periodontally compromised patients is comparable with the situation seen in healthy patients remains to be seen (2). Periodontitis has been divided into aggressive and chronic subtypes (3). Aggressive periodontitis can be encountered in localized and generalized forms, and the latter has been found to harbor certain kinds of bacteria more frequently than the former (4).

Chronic periodontitis is caused by colonization of the subgingival area by other known microorganisms (5). The condition has recently been associated with additional phylotypes and named species (6).

Although periodontitis is considered a multifactorial disease (7), genetic factors may explain about 50% of cases (8).

Individual susceptibility is another key factor that plays an important part in the destruction of soft and hard tissues around the teeth in periodontally compromised patients (7).

If it is not diagnosed and treated, periodontitis may lead to the breakdown of the soft and hard tissues supporting the teeth.

It has been reported that the bacteria in the periodontal sulci of affected teeth may also colonize recently-inserted dental implants and thus jeopardize the long-term survival of the implants due to peri-implant tissue destruction (9).

Partially and totally edentulous patients have different periodontal microorganisms (10). The peri-implant sulci of partially edentulous patients harbor more motile rods and spirochetes than those of fully edentulous individuals (10-13). As a consequence, the surfaces with peri-implantitis of implants fitted in partially edentulous individuals are found to harbor *Actinobacillus actinomycetemcomitans*, *Porphyromonas gingivalis* and *Prevotella intermedia* more frequently than successful implants (14).

Peri-implantitis, like periodontitis around teeth, may thus act as a major contributor to implant failure (1).

It is therefore reasonable to assume that patients with implant-supported restorations who had previously suffered from periodontal disease are at higher risk of developing a peri-implantitis.

This means that periodontal therapy is essential before implants are placed in partially edentulous patients (15).

Any infections must be brought under control and patients must follow a maintenance program based on a strict three-month recall protocol. Home care must be reinforced, and patients must maintain a high standard of daily oral hygiene (16).

The procedures involved are complex and the patient's cooperation is indispensable, particularly in the preparatory stages of rehabilitations involving implants, during oral hygiene procedures, non-surgical and surgical periodontal therapies, and implant placement, and also afterwards, during the maintenance phase.

Clinical conditions in which a patient's compliance with the procedures required is limited due to physical or behavioral problems may suffer from a higher failure rate.

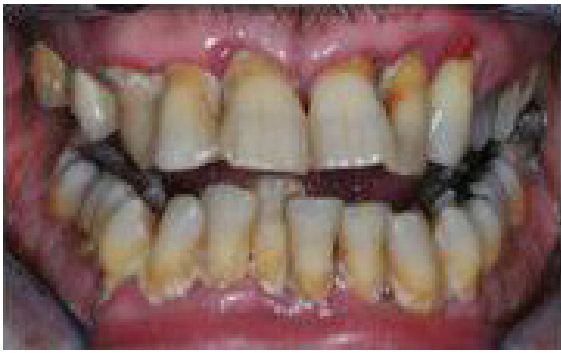This article reports on the clinical management of a patient with a picture of increasingly severe physical disability caused by neoplastic disease, who was treated for severe chronic periodontitis, then fitted with 6 implants and followed up for 2 years.

## Methods

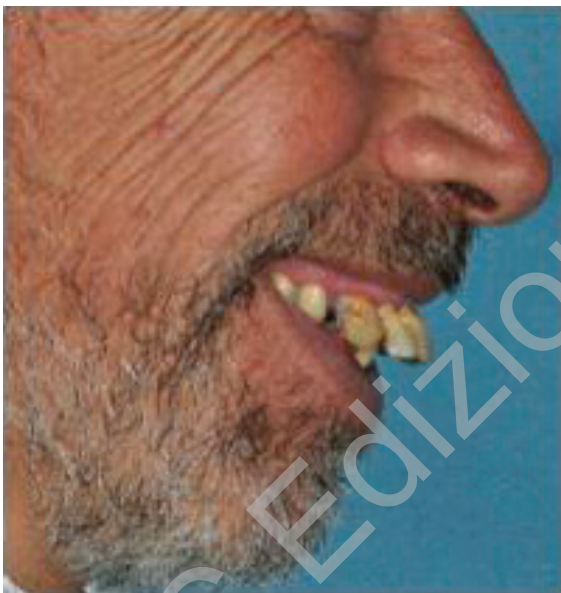
The complex perio-implant and prosthodontic case described was a 54-year-old man, a manager with a high socio-cultural level, suffering from meningeal melanomatosis, presenting to a private-practice dental office with severe signs and symptoms of severe and generalized chronic periodontitis (Figs. 1-4).

The patient is married with two children.

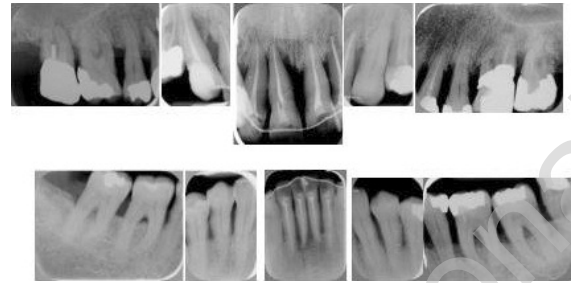
His neoplastic disease is located at the meningeal level of the spinal cord. It had been diagnosed eight years earlier and had led to increasingly severe muscle weakness affecting the low-



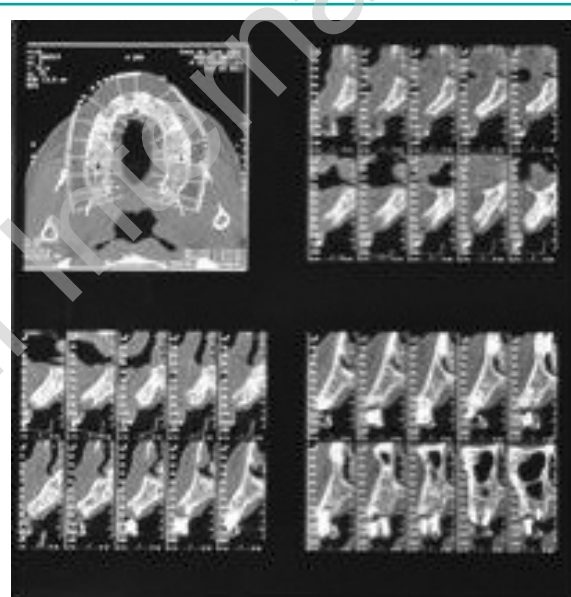
**Figure 1**  
Preoperative outline of the dental clinical situation (oral view).



**Figure 2**  
Preoperative outline of the dental clinical situation (lateral view).



**Figure 3**  
Preoperative periapical Rx examinations.



**Figure 4**  
Tomography at preimplant Treatment phase.

er limbs, making deambulation difficult and causing abdominal problems. When the treatment with dental implants began, the patient was still able to walk unassisted and, despite his organic disease, he had adapted sufficiently to be still working during this phase of his dental treatment. In the early part of his dental treatment, all procedures were completed under loco-regional anesthesia.

A comprehensive periodontal examination was conducted before any dental treatment was planned. After completing the diagnostic work-up, the affected teeth from 1.3 to 2.3, and from 3.2 to 4.2 were extracted. Tooth 1.7 was also extracted. A provisional fixed restoration was fashioned to rehabilitate all the patient's natural dentition and his missing teeth.

The patient was prescribed oral hygiene therapy and underwent root planing of all his residual teeth.

Endodontic therapies were administered to all the teeth due to a high dentinal sensitivity and

pre-prosthetic crown reconstructions were performed.

Periodontal surgery with modified Widman flaps was then accomplished on all the teeth.

At the end of this initial phase of the treatment, the patient's clinical conditions suddenly deteriorated drastically and he was no longer able to walk, he had to use a wheelchair. This made it necessary for the dentist to make considerable changes to the treatment plan and strategies for managing the patient's analgesia and support to enable him to tolerate the dental treatments. The patient's worsening physical conditions also led to atrophy of the abdominal musculature and lower limbs, and faecal incontinence. From the mental standpoint, in this phase of progression of his neoplastic disease, the patient showed signs of anxiety and a marked change of mood, with a declining spirit of initiative and lesser capacity to take care of his personal hygiene.

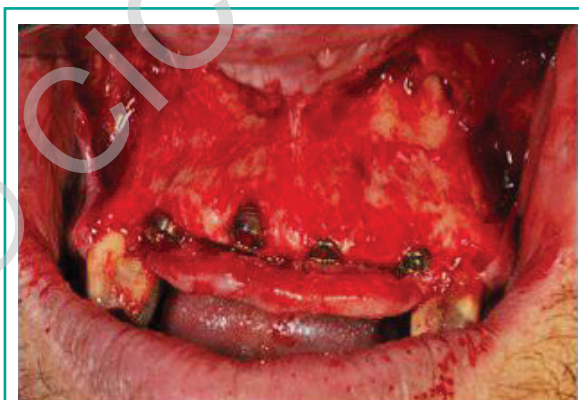
From the behavioral standpoint, the patient's psychophysical conditions made it necessary to interrupt the dental treatment sessions because he was less able to adopt and maintain the postures needed to complete the dental treatment, and he was also paying less attention to his oral hygiene.

Three months later, four maxillary implants were inserted in positions 1.3, 1.1, 2.1 and 2.3 (Fig. 5), and two mandibular implants in positions 3.2 and 4.2. During the placement of the

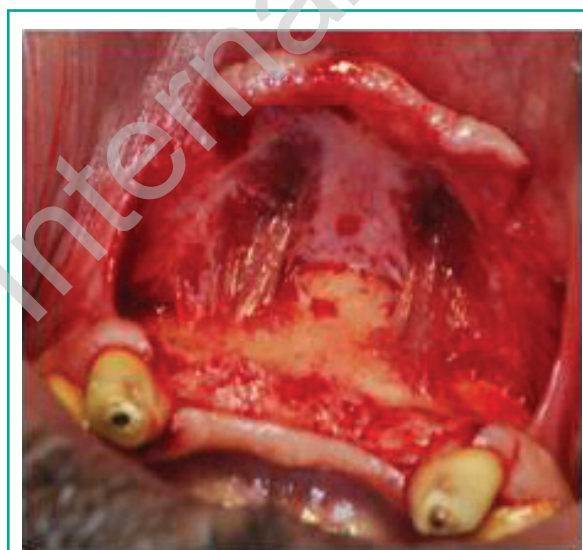mandibular implants, the mental muscles were isolated and detached to be preserved and to enable an appropriate guided bone regeneration at these sites (Figs. 6, 7).

During the implant surgery, the patient was administered intravenous sedation due to concern about his systemic conditions.

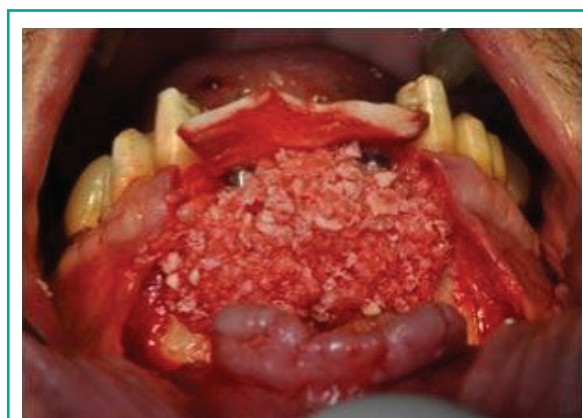The support resources available to help deal with the patient's changed general conditions were assessed. In particular, the problem of his



**Figure 5**  
Superior Implants in Position 1.3,1.1,2.1,2.3.



**Figure 6**  
Mental muscles insertions.



**Figure 7**  
Inferior implants in position 3.2 and 4.2 and the bone graft and the reabsorbable membrane in position.

behavioral management was discussed with the supervision of a physician specialized in clinical psychology, a university researcher interested in physician-patient communications. This specialist was also consulted to provide emotional support for the dentist engaging in the ongoing management of a patient suffering so severely.

Despite the distress and the difficulties of adapting to the effects of his disease, the patient continued to make plans for the future and was constantly seeking practical solutions to the problems of his daily life.

For instance, although the dental surgery was equipped with a special dental chair for disabled patients, who could remain seated position in their own wheelchair, the patient preferred to make the effort to transfer from his wheelchair to the dental chair.

Based on observations of the patient's behavior, the dentist and mental health specialist agreed to call in an anesthetist to treat the patient with titrated sedation during the surgical procedures, depending on the needs of the treatment, while continuing the treatments in the outpatient setting (17, 18). The amnesic effect of the sedative drugs was judged to be helpful in reducing the patient's perception of the discomfort caused by the treatments.

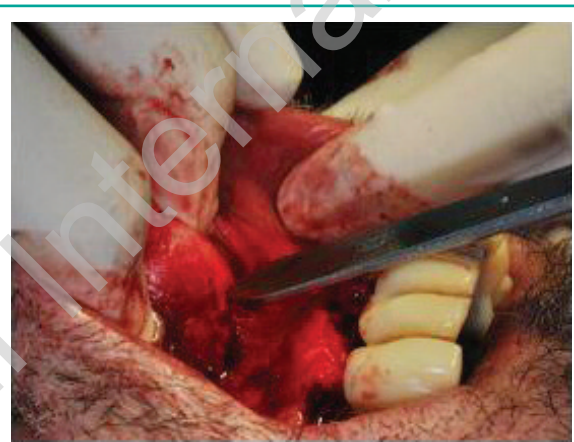The patient thus underwent conscious sedation. Oxygen was initially administered for 5 minutes. Then nitrous oxide and oxygen were administered together to reach the baseline for the patient's sedation, which was 40% nitrous oxide and 60% oxygen. Then midazolam was titrated intravenously to obtain amnesia, up to a dose of 6.0 mg given the length of the surgical procedures. After the first 1.0 mg of midazolam had been administered, local anesthesia was induced by infiltrating 2% xylopylin (Lidocaine 1:50,000 adrenalin) (Dentsply Italia s.r.l., Rome, Italy).

At the end of the surgical procedures, oxygen was administered for 10 minutes and the patient was monitored closely until he recovered completely.

Five months later, the implants and teeth were rehabilitated with fixed metal-ceramic bridges on both jaws. In regards to the upper prosthetic

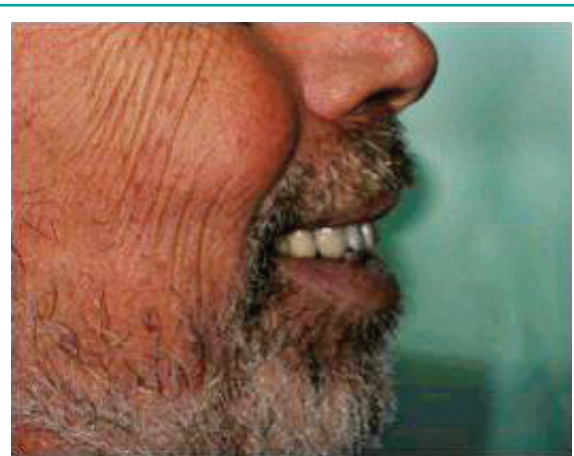
rehabilitation, the central incisors margins of the temporary fixed rehabilitation were kept vertical to the anterior nasal spine for esthetic and phonetic reasons, given the lack of previous reference points (Figs. 8, 9).

Based on the previously-ascertained reference points, the difference in bone height was calculated between the radiographs taken at the time of inserting the implants and those taken subsequently during the follow-up.



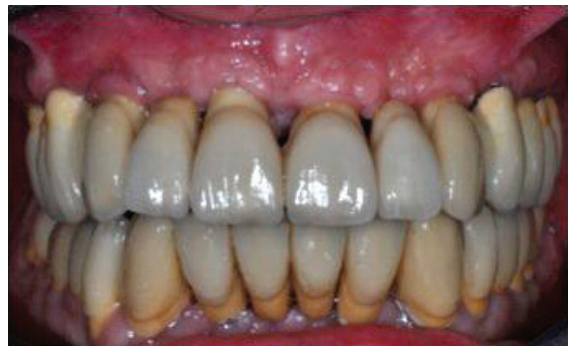**Figure 8**

The intraoperative evaluation of the position of the superior incisors marginal edges of the temporary restoration relatively to the anterior nasal spine.



**Figure 9**

Superior Aesthetic Remarks.



**Figure 10**  
The rehabilitation 2 years after loading.

## Results

The health of the periodontally treated teeth improved considerably, and the mean alveolar bone loss was 0.30 mm after a 2-year observation period.

With time, the patient's compliance both to therapeutic maneuvers conducted in the studio and to the medical prescriptions at home also improved. In particular, he was once again willing and cooperative, doing his part in the treatment, partly thanks to his ongoing and trusting relationship with his dentist. This also led to an improvement in his handling of his oral hygiene at home (Fig. 10).

## Discussion

It has been reported that the long-term survival rates of implants inserted in partially edentulous patients with chronic periodontitis may exceed 90%, making them comparable with those seen in the general population (19), but it would be prudent to assume that this is still a matter of debate (2).

The periodontal probing depth around implants in periodontally compromised patients continues to increase over a long period of time, and there is likely to be a significant difference in the mean peri-implant marginal bone loss between

patients with a history of chronic periodontitis and patients who are periodontally healthy (9). In partially edentulous patients, these phenomena are due to translocation of the periodontal micro-flora from diseased teeth to the surfaces of the implant, which can lead to the onset of peri-implantitis (20, 21).

Leonhardt et al. (9) also said that, when peri-implant tissue breakdown occurs, this does not appear to be related exclusively to the pathogenic periodontal microorganisms emerging from the periodontal pockets around diseased teeth; it is the result of complex interactions between the micro-flora and host factors.

Based on the above considerations, implant-supported prosthetic rehabilitation in patients with a history of periodontitis is a challenge and these patients are more likely to develop complications around their implants and consequently experience implant loss (22). It is essential to control any periodontal disease before placing implants to avoid this particular patient population having a lower implant treatment success rate (1, 9). Nowadays, a variety of non-surgical and surgical procedures are available to clinicians for the proper treatment of the possible combinations of hard and soft tissue defects caused by periodontal disease.

Our findings support the hypothesis that the prognosis of implants inserted in periodontally compromised subjects may be less favorable than in periodontally healthy patients, and that a maintenance program including a regular three-month recall is essential to keep the periodontal and peri-implant tissues healthy (23).

## Conclusions

It is of paramount importance to control periodontal disease before inserting implants in patients with severe chronic periodontitis, and a regular recall program is essential to ensure the health of the periodontal and peri-implant tissues. The management of patients with complex psychophysical needs like the one described here is emotionally taxing, but feasible if the dental

treatment is provided by a team designed to meet all the patient's needs on various levels.

## Disclosure

The authors have no conflict of interest to disclose.

## References

1. Van der Weijden GA, van Bommel KM, Renvert S. Implant therapy in partially edentulous periodontally compromised patients: a review. *J Clin Periodontol* 2005;32:506-511.
2. Schou S, Holmstrup P, Worthington HV, Esposito M. Outcome of implant therapy in patients with previous tooth loss due to periodontitis. *Clin Oral Implants Res* 2006;17 (Suppl 2):104-123.
3. Armitage GC. Development of a classification system for periodontal diseases and conditions. *Ann Periodontol* 1994;4:1-6.
4. American Academy of Periodontology. Parameter on aggressive periodontitis. *J Periodontol* 2000;71:867-869.
5. Wilson M. Biological activities of lipopolysaccharides from oral bacteria and their relevance to the pathogenesis of chronic periodontitis. *Sci Prog* 1995;78 (Pt 1):19-34.
6. Kumar PS, Griffen AL, Barton JA, Paster BJ, Moeschberger ML, Leys EJ. New bacterial species associated with chronic periodontitis. *J Dent Res* 2003 May;82(5):338-44.
7. Page RC, Offenbacher S, Schroeder HE, Seymour GJ, Kornman KS. Advances in the pathogenesis of periodontitis: summary of developments, clinical implications and future directions. *Periodontology* 2000 1997;14:216-248.
8. Michalowicz BS, Diehl SR, Gunsolley JC, Sparks BS, Brooks CN, Koertge TE, Califano JV, Burmeister JA, Schenkein HA. Evidence of a substantial genetic basis for risk of adult periodontitis. *J of Periodontol* 2000;71:1699-1707.
9. Leonhardt A, Adolfsson B, Lekholm U, Wikstrom M, Dahlen G. A longitudinal microbiological study on osseointegrated titanium implants in partially edentulous patients. *Clin Oral Implants Res* 1993;4:113-120.
10. Apse P, Ellen RP, Overall CM, Zarb GA. Microbiota and crevicular fluid collagenase activity in the osseointegrated dental implant sulcus: a comparison of sites in edentulous and partially edentulous patients. *J Periodontol Res* 1989;24:96-105.
11. Mombelli A, Marxer M, Gaberthuel T, Grunder U, Lang NP. The microbiota of osseointegrated implants in patients with a history of periodontal disease. *J Clin Periodontol* 1995;22:124-130.
12. Danser MM, Van Winkelhoff AJ, Van Der Velden U. Periodontal bacteria colonizing oral mucous membranes in edentulous patients wearing dental implants. *J Periodontol* 1997;68:209-216.
13. Van Winkelhoff AJ, Goene RJ, Benschop C, Folmer T. Early colonization of dental implants by putative periodontal pathogens in partially edentulous patients. *Clin Oral Implants Res* 2000;11:511-520.
14. Leonhardt A, Renvert S, Dahlen G. Microbiological findings at failing implants. *Clin Oral Implants Res* 1999;10:339-345.
15. Bragger U, Burgin WB, Hammerle CHF, Lang NP. Associations between clinical parameters assessed around implants and teeth. *Clin Oral Implants Res* 1997;8:412-421.
16. Chee W. Peri-implant management of patients with aggressive periodontitis. *J Calif Dent Assoc* 2011;39:416-419.
17. Caputo AC. Providing deep sedation and general anesthesia for patients with special needs in the dental office-based setting. *Spec Care Dentist* 2009; 29(1):26-30.
18. National Dental Advisory Committee. Conscious sedation in dentistry - dental clinical guidelines. Scottish Dental Clinical Effectiveness Programme. Dundee: Dundee Dental Education Centre, 2006:1-48.
19. Karoussis IK, Kotsovilis S, Fourmousis I. A comprehensive and critical review of dental implant prognosis in periodontally compromised partially edentulous patients. *Clin Oral Impl Res* 2007;18:669-679.
20. Meffert RM. Periodontitis and peri-implantitis: one and the same? *Practical Periodontics and Aesthetic Dentistry* 1993;5:79-80,82.
21. Nevins M. Will implants survive well in patients with a history of inflammatory periodontal disease. *J of Periodontol* 2001;72:113-117.
22. Al-Zahrani MS. Implant therapy in aggressive periodontitis patients: a systematic review and clinical implications. *Quintessence Int* 2008 Mar;39(3):211-215.
23. Kim KK, Sung HM. Outcomes of dental implant treatment in patients with generalized aggressive periodontitis: a systematic review. *J Adv Prosthodont* 2012 Nov;4(4):210-217.

Correspondence to:  
Dott. Riccardo Tizzoni  
E-mail: tizzoni.med@libero.it