

NEW TECHNIQUE FOR INTER-IMPLANT PAPILLA RECONSTRUCTION BETWEEN TWO OR MORE IMPLANTS IN PATIENTS WITH VARIABLY REABSORBED RIDGES AND FLAT ANATOMY. PRELIMINARY RESULTS OF A 9 CONSECUTIVE CLINICAL CASE SERIES

R. TIZZONI¹, M. TIZZONI²

¹M.D. and D.D.S. Private practice, Milan, Italy; ²M.D. and D.D.S. Private practice, Milan, Italy

SUMMARY

New technique for inter-implant papilla reconstruction between two or more implants in patients with variably reabsorbed ridges and flat anatomy. Preliminary results of a 9 consecutive clinical case series.

The aim of the work. Interimplant papilla reconstruction is difficult because the biologic width around an implant is apical to the implant-abutment connection and because the biologic width creates subcrestally. The aim of this study is to investigate whether the reconstruction of the interimplant papilla can be achieved by the use of an innovative surgical technique combined with scalloped implants, in the most severe surgical conditions, i.e. in variably reabsorbed ridges with flat anatomy.

Materials and method. Nine surgical sites, in eight consecutive patients, were treated with at least two adjacent scalloped implants and fixed prosthesis. 23 scalloped implants were placed using this new surgical technique on bone and soft tissue structures. One flat platform implant was also placed between two other scalloped implants. A total of 15 interimplant papillae were examined.

Results. 100% of papilla reconstruction at first prosthesis insertion. 13.3% failed to maintain interimplant papillae after 6 months and 20% after 12 months. Also, papilla reconstruction was maintained for 12 months in the mesial and distal embrasure spaces of the flat platform implant.

Conclusion. The combination of the use of adjacent scalloped implants with this surgical approach, even in reabsorbed ridges with flat anatomy, may reform interimplant bone peaks as support for the papillae.

Key words: inter-implant papilla reconstruction/regeneration, scalloped implants, implant design, esthetics, dental papilla.

RIASSUNTO

Nuova tecnica chirurgica per la ricostruzione della papilla interimplantare fra due o più impianti in pazienti con vario grado di atrofia delle creste alveolari ed architettura anatomica piatta. Risultati preliminari di una serie di 9 casi clinici consecutivi.

Scopo del lavoro. La ricostruzione della papilla interimplantare è difficile perché l'ampiezza biologica in implantologia si forma apicalmente alla connessione moncone-impianto e pertanto è a livello sottocrestale. Questo studio si propone di verificare se può essere ottenuta la ricostruzione della papilla interimplantare, grazie ad un'innovativa tecnica chirurgica utilizzata in combinazione ad impianti festonati, nelle condizioni cliniche più severe e cioè in creste alveolari atrofiche ad architettura anatomica piatta.

Materiali e metodi. Sono stati trattati consecutivamente nove siti chirurgici in otto pazienti, i quali richiedessero almeno due impianti festonati adiacenti e riabilitazione protesica fissa. Sono stati inseriti 23 impianti festonati secondo la nuova tecnica, prevista sia per i tessuti duri che molli. È stato anche inserito un impianto a testa piatta fra altri due impianti festonati. Sono state studiate 15 papille interimplantari.

Risultati. Alla consegna dei manufatti protesici si è ottenuto il 100% di ricostruzione papillare interimplantare. Nel 13.3% dei casi non si è mantenuta la ricostruzione papillare interimplantare dopo 6 mesi e nel 20% dei casi dopo 12 mesi. È stata anche ottenuta, e mantenuta per 12 mesi, la ricostruzione dalle papille interimplantari mesiale e distale relativa all'impianto a testa piatta.

Conclusioni. La combinazione dell'utilizzo di questa nuova tecnica chirurgica con impianti festonati adiacenti sembra poter riformare picchi ossei interimplantari di supporto per le papille gengivali perfino in caso di creste alveolari variabilmente atrofiche e con anatomia ossea piatta.

Parole chiave: ricostruzione/rigenerazione della papilla interimplantare, impianti festonati, disegno implantare, estetica, papilla dentale.

Introduction

In the anterior maxillary area the shape and size of the gingival papillae play a crucial role in the esthetic outcome of oral implant rehabilitation.

It is well established that reconstruction of inter-implant papilla is a technique sensitive approach dependent on clinician's skill and knowledge, and its reliability, especially long term, is still a matter of debate (1-4).

Tarnow et al. (5) demonstrated that in natural dentition the interdental papilla is present nearly 100% of the cases when the distance between the dental crown contact point and the alveolar bone crest is 5 mm or less.

It is also known that in a single-tooth implant supported restoration the shape of the papilla is mainly influenced by the coronal position of the alveolar crest of the adjacent tooth (6,7) and the contact point (8-10): these interactions, however, are not always established around implants (11).

A reason why reconstruction of the gingival papilla between two or more implants is very difficult and unpredictable is because the biologic width around an implant is apical to the implant-abutment connection (12) and to the crest of bone. In such a situation the connective tissue and the epithelial attachment are not supportive of the inter-implant papilla (2).

From a literature research only few published articles reported about results of inter-implant papilla reconstruction (13,14).

As described by Tarnow et al. (15), in order to prevent the risk of bone reabsorption between implants, a key role is played by inter-implant distance that should be at least 3 mm.

This seems to be related to the horizontal component of the biologic width that forms around implants. The average height of tissue from the crest of bone to the top of the papilla between adjacent implants is 3,4 mm (2).

Consequently the height of the bone crest often influences the presence of a papilla in the inter-implant space (2,3): this shows that predictable esthetic results can only be achieved in cooperation with subjacent bone level (6).

In this respect in the past decades several surgical techniques have been described by different authors to correct bone atrophies and crest deformities (16-27).

More recently the preservation of the inter-implant bone crest, by means of post-extractive immediate implant placement, was reported to be paramount important especially in the maxillary anterior area where esthetic demands are higher (28-30).

Furthermore in order to maximize the chances for good tissues health, soft tissue profiles and maintenance of septal bone height, immediate post-extractive implants with immediate provisionalization have also been proposed (31,32): this approach was reported to get high survival rates (33).

As regards the role of the macrodesign of implants, notably in their most coronal part, Wohrle stated that the use of scalloped implants inserted in preserved osseous anatomy, with interproximal bone peaks and lower buccal and lingual crests, also significantly decreases interproximal bone remodelling (34).

The scalloped implant was conceived for patients with preserved three-dimensional ridge morphology and it was also stated that this design only offers the potential to reconstruct previously lost interproximal bone peaks (34).

In light of the above issues, a study was carried out to assess whether the reconstruction of an inter-implant papilla between two or more implants could be achieved by a new surgical technique on bone and soft tissue structures combined with scalloped implants.

Patients and methods

Between November 2006 and May 2007 eight consecutive patients (4 males and 4 females), aged between 18 e 58 years (mean 38 years) requiring implants and fixed prosthesis in any region of both jaws, were treated with Nobel Perfect groovy scalloped implants combined with this novel surgical approach. Total number of scalloped implants was 23. 1 Nobel Replace implant was also inserted between two other Nobel Perfect scalloped implants. All the implants were two-stage implants and placed in healed sites, morphologically stable and with comple-

ted bone maturation processes. All the treated areas presented variably reabsorbed ridges with flat anatomy (i.e. preservation of the inter-dental bone peak was not considered in this particular study).

Before treatment informed written consent was obtained from all the subjects. Patients were selected according to the following inclusion criteria: a recipient bone site allowing the placement of at least two adjacent implants with a minimum length of 10 mm and a minimum diameter of 4,3 mm at the head portion; controlled oral hygiene. In addition to exclusion criteria universally accepted in implant surgery (35), the following exclusion criteria were adopted: heavy smokers (more than 15 cigarettes a day), unrealistic expectations about the procedure, bruxism and/or parafunctional habits. All patients but one were treated without need of bone augmentation procedures. In one case, because of a car accident, bone morphology was only corrected for ideal three-dimensional positioning of the implants. In order to achieve stabilization, three patients underwent sinus lift procedure and implant placement at the same time. Periodontal plastic surgery was not performed in any patient in the area of the papillae. Information included complete medical and dental history, and clinical and radiographic evaluation. Photographs of the area intended to be treated were also taken.

Description of the new technique

Surgical templates were used to determine implants positioning.

Local anesthesia was induced by infiltration with xyloplina 2% (Lidacain 1:50.000 adrenaline) (Dentsply Italia s.r.l. Roma, Italy).

After crestal incision a mucoperiosteal flap was elevated. For a better surgical exposure, when necessary, releasing incisions were made.

A first osteotomy for implant placement was performed according to the manufacturer's instruction. A second osteotomy was then performed, by using of a round bur, from the buccal to the lingual aspect of the alveolar bone (Buccal-Palatal Osteotomy: BPO, or Buccal-Lingual Osteotomy: BLO) to remove

an adequate quantity of bone on the vestibular and lingual aspects of the alveolar ridge. This procedure permitted the scalloped outline of the implant collar to adapt to the reconstructed scalloped anatomy of the bone while generating immediate interimplant bone peaks (Figs. 1 and 2).

Whenever possible all the implants were inserted 3 mm apart. At first stage surgery the implant collar was positioned 1,04 mm above the alveolar crest on an average (Fig. 3).

All the implants got a primary implant stability of at least 25 Ncm.

The wound margins were allowed to heal with stratified sutures: first horizontal mattress sutures were used and then superimposed uninterrupted sutures to stabilize the most coronal portion of the flap (Fig. 4).

Antibiotics, anti-inflammatory drugs and chlorhexidine mouth wash were prescribed to all patients.

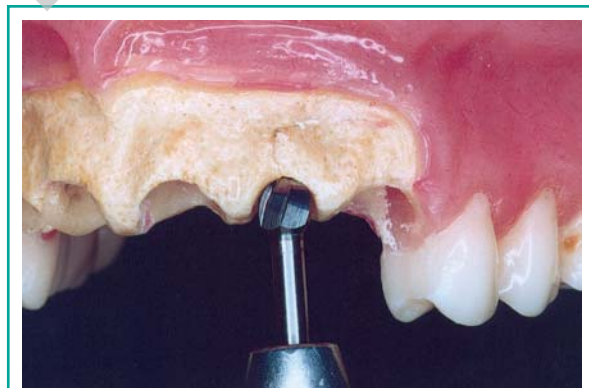

Figure 1

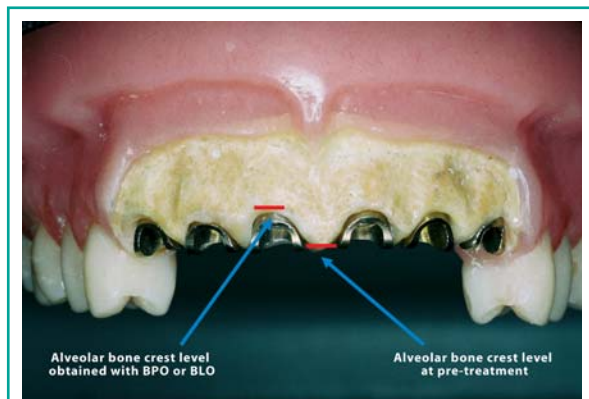
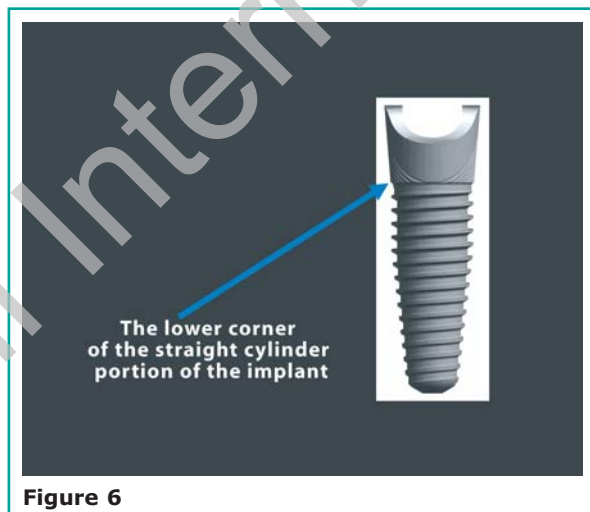
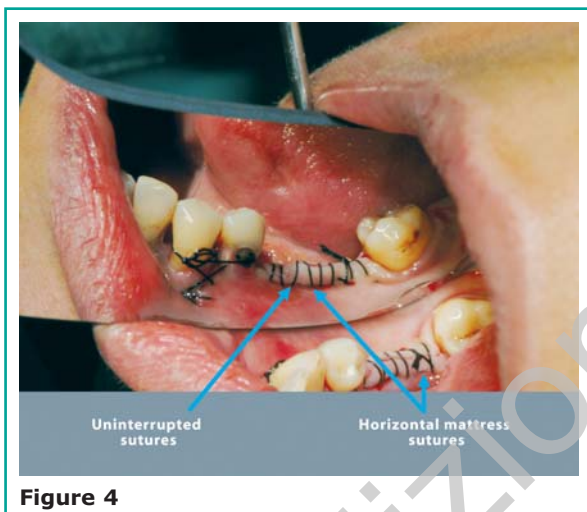
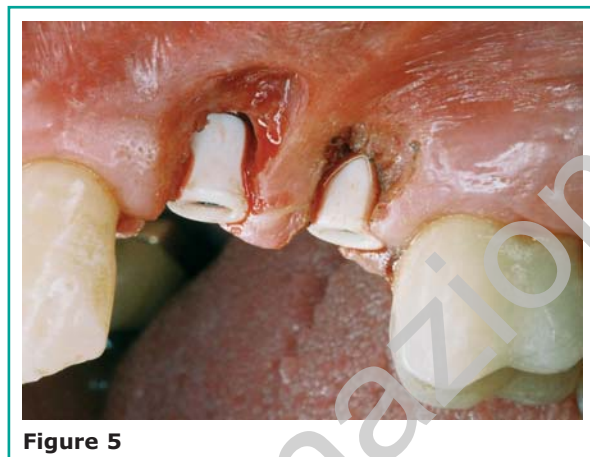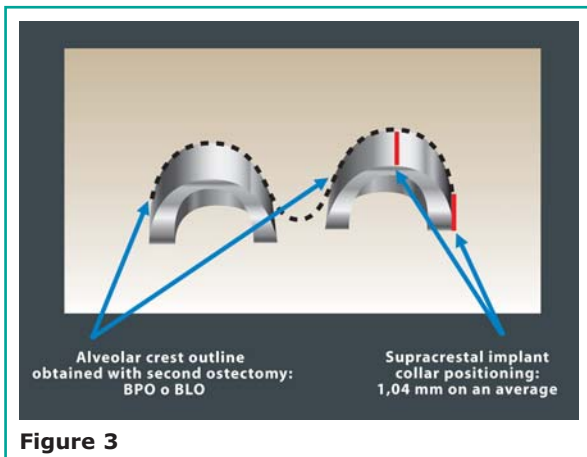


Figure 2



Sutures were removed after 7 days and the patients were seen monthly for prophylaxis.

All the implants healed submerged: time of healing was 2 to 5 months (mean 3,5 months) in the mandible and 5 to 8 months (mean 6,5 months) in the maxilla.

With the use of the surgical template to identify implant location, second stages surgery was flapless and performed by the round tip of an electro-surgical device (Ida Surgery, Italy). In order to obtain a scalloped shape of the soft tissue, an accurate gingivectomy following implant head outline was made on both the vestibular and the lingual aspects (Fig. 5).

All the implants were rehabilitated with free standing crowns.

At implant placement a photograph of the implant

position with open flap and a radiograph with Rinn centrator (Dentsply, Elgin, Illinois, U.S.A.) were taken.

As regards registration during follow up, for each patient, photographic evaluation of the length of the papilla and assessment of the soft tissue contour adjacent to the implant, and radiographic measurements of the first bone to implant contact were made at the following time-points: permanent prosthesis delivery, 6 and 12 months after loading respectively. The lower corner of straight cylinder portion of the implant was used as a reference point for radiographic measurements (Fig. 6).

The first bone to implant contact was recorded above or below the reference point. Digital radiographs were obtained and viewed on a liquid crystal display computer screen using a scanner. Each ra-

diograph was analysed by a software and measurement made by a dedicated software (Digora, Soredex, Helsinki, Finland). Measurements were obtained on both the mesial and the distal aspect of each implant.

Concerning implants distribution for position and type, they are depicted in Table 1.

A total of 15 inter-implant embrasure spaces were examined.

Results

All implants were stable and successfully in function at one year follow-up resulting in 100% cumulative survival rate (Table 2).

Radiographic data: marginal bone level at implant placement and 6 and 12 months after loading are shown as average (mesial + distal / 2) in Table 3.

Table 4 depicts marginal bone remodelling after 6

and 12 months from loading always expressed as average (mesial + distal / 2).

Compared to another study (36), radiographic results at follow-ups time of the present study show bone levels above the reference point at a higher percentage.

In most of the cases the new technique was consistent for inter-implant papilla reconstruction. Out of the 15 embrasure spaces analysed, 100% showed papilla reconstruction at first prosthesis insertion, only 2 (13.3%) failed to maintain inter-implant papillae after a 6 months follow-up period and 3 (20%) after 12 months of follow-up time. Notably papilla reconstruction was also achieved and maintained for a 12 months follow-up period, in the mesial and distal embrasure spaces of the flat platform Nobel Replace implant positioned between two other Nobel Perfect scalloped implants.

It was observed that the smaller was the bone remodelling the longer the papilla occurred.

Table 1

Implants distribution for position and type

| MAXILLA | | | | | | | | | | | | | | | | |
|---------------|----|----|----|----|----|----|----|----|----|----|----|----|----|----|----|----|
| Position | 18 | 17 | 16 | 15 | 14 | 13 | 12 | 11 | 21 | 22 | 23 | 24 | 25 | 26 | 27 | 28 |
| N of implants | | | | 1 | 1 | | 2 | 2 | 2 | 2 | 1 | 1 | 3 | 2 | | |
| Diam 3.5 mm | | | | 1 | 1 | | 2 | 1 | 1 | 2 | 1 | 1 | 2 | | | |
| Diam 4.3 mm | | | | | | | | 1 | 1 | | | | | | | 1 |
| Diam 5.0 mm | | | | | | | | | | | | | 1 | | | 1 |
| Length 10 mm | | | | | | | 1 | | | | | | 1 | | | |
| Length 13 mm | | | | 1 | 1 | | 1 | 2 | 2 | 2 | 1 | 1 | 2 | 2 | | |
| MANDIBLE | | | | | | | | | | | | | | | | |
| Position | 48 | 47 | 46 | 45 | 44 | 43 | 42 | 41 | 31 | 32 | 33 | 34 | 35 | 36 | 37 | 38 |
| N of implants | | 1 | 2 | 1 | | | | | | | | | 1 | 1 | | |
| Diam 3.5 mm | | | | | | | | | | | | | | | | |
| Diam 4.3 mm | | | | 1 | | | | | | | | | 1 | | | |
| Diam 5.0 mm | | 1 | 2 | | | | | | | | | | | | 1 | |
| Length 10 mm | | | | 1 | 1 | | | | | | | | 1 | 1 | | |
| Length 13 mm | | 1 | 1 | | | | | | | | | | | | | |

1 Nobel Replace implant in position 24 (length: 13mm; diameter: 3.5 mm) was also placed, between two other Nobel Perfect implants.

Table 2

| Time period | Implants | Failed | WD | CSR % |
|-----------------------|----------|--------|----|-------|
| Insertion to 3 months | 24 | 0 | 0 | 100 |
| 3 months to 6 months | 24 | 0 | 0 | 100 |
| 6 months to 12 months | 24 | 0 | 0 | 100 |

Table 3

Bone levels presented as averages, (mesial + distal)/2.
Positive numbers indicate bone levels coronal to the reference point.
Reference point: the lower corner of the straight cylinder portion of the implant

| | INSERT | | 6 MO | | 12 MO | |
|----------------|--------|------|------|------|-------|------|
| Mean | 2.96 | | 1.44 | | 0.80 | |
| N | 23 | | 23 | | 23 | |
| | n | % | n | % | n | % |
| > 2.0 | 21 | 91.3 | 6 | 26.1 | 3 | 13 |
| 1.01 --- 2.0 | 2 | 8.7 | 8 | 34.8 | 9 | 39.1 |
| 0.01 --- 1.0 | 0 | 0 | 7 | 30.4 | 4 | 17.4 |
| -0.9 --- 0.0 | 0 | 0 | 2 | 8.7 | 6 | 26.1 |
| -2.01 --- -1.0 | 0 | 0 | 0 | 0 | 1 | 4.4 |

Clearly, in patients showing unfavourable interarch relationship, where oral-implant rehabilitations with long prosthetic crowns were needed, papillae fully filling the interdental embrasure spaces were not achieved according to the statement that the average height of tissue from the crest of bone to the top of the papilla between adjacent implants is 3,4 mm (2) (Figs. 7, 8 e 9: clinical cases at 1 year follow-up).

Discussion

The difficulty of reforming a papilla between two implants has been related to the fact that flat platform

implants place the biologic width subcrestally and apically to the implant-abutment connection (12). On the contrary in natural healthy dentition the biologic width always creates supracrestally and bone peak that exists between an implant and a tooth or two adjacent teeth is supportive of the papilla (2). Thus, alternate implant design supportive for bone peaks and gingival papillae have been advocated (2) and bone augmentation procedures before placing two adjacent implants in the esthetic zone has been suggested (2); Grunder et al. (37) confirmed that most cases of aesthetics need bone augmentation procedures on the buccal aspect and interproximal area of implants; Grossberg (4) considered bone and soft tissue augmentation procedures the most suc-

Table 4

Bone remodelling data from all available radiographs. Bone remodelling presented as average, (mesial + distal)/2.

Positive numbers indicate bone loss.

Reference point: the lower corner of the straight cylinder portion of the implant

| | | INSERT TO 6MO | | INSERT TO 12MO | |
|-----------------------|--|---------------|----------|----------------|----------|
| Mean | | 1.52 | | 2.16 | |
| N | | 23 | | 23 | |
| | | n | % | n | % |
| > 2.0 | | 7 | 30.4 | 8 | 34.8 |
| 1.01 --- 2.0 | | 7 | 30.4 | 11 | 47.8 |
| 0.01 --- 1.0 | | 9 | 39.2 | 4 | 17.4 |
| -0.9 --- 0.0 | | 0 | 0 | 0 | 0 |
| -2.01 --- -1.0 | | 0 | 0 | 0 | 0 |

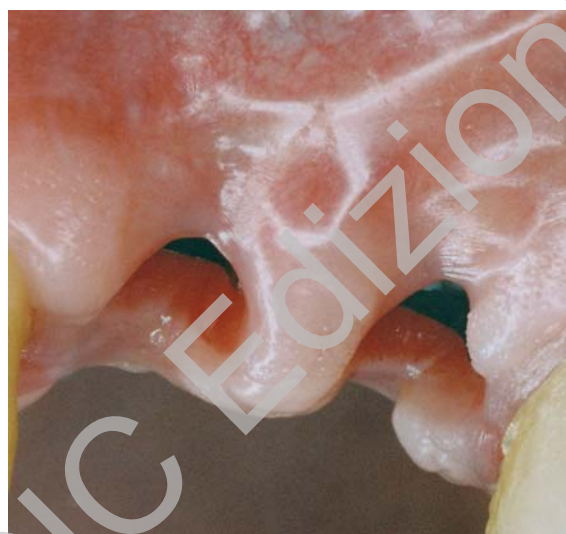

Figure 7

successful method of achieving an aesthetic outcome. Wohrle proposed to adopt guided bone regeneration procedures to create a peak of bone between two scalloped implants (34), but these procedures are dependent on clinician's skill and could be very unpredictable due to variable bone reabsorption (38). This augmented bone would then need to be main-

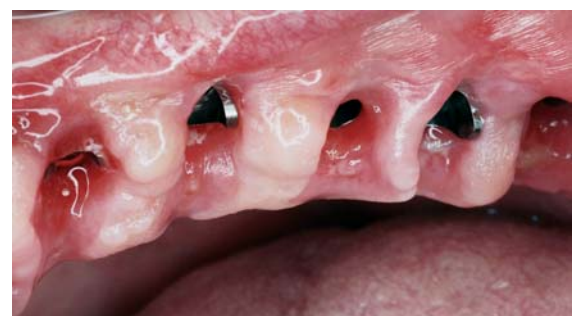

Figure 8

tained by placing the implants at least 3 mm apart (15). In this specific study, in case of scanty of space (1 patient, 2 embrasures spaces), it was impossible to insert all of the implants 3 mm apart, because the narrowest implant had a 4,3 mm diameter at the head portion. As a consequence more bone remodelling and less papillae reconstruction were expected and noted.

Implants with narrower heads may be necessary for certain clinical cases.

It should now be emphasized that vestibular osseous plate preservation was not taken into consideration in this study, undercontour of the labial

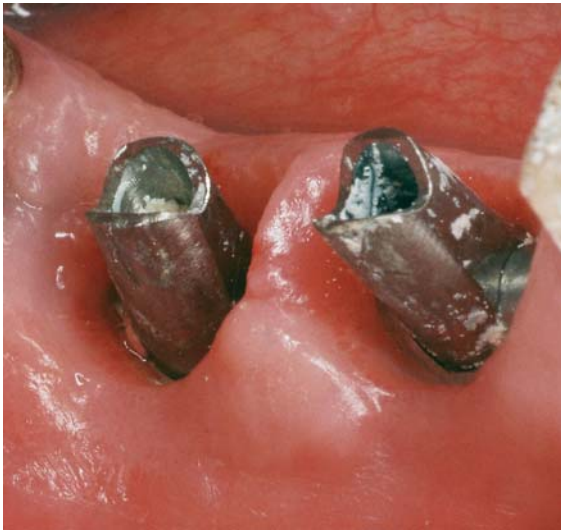

Figure 9

emergence profile of the prosthetic restoration was not performed and the platform shifting concept was not applied in this particular study.

Moreover, if bone and soft tissue augmentation procedures had been applied in order to vertically increment the sites undergoing implant therapy, a more favourable interarch relationship would have been obtained and, probably, better inter-implant papillae reconstruction.

For the reason of significant crestal bone loss that occurs following abutment loosening and tightening (39-41), implants were not provisionalized and final prosthesis was delivered without temporary prosthesis with no soft tissue conditioning.

Another consideration is that the second technique associated osteotomies (BLO: buccal-lingual osteotomy or BPO: buccal-palatal osteotomy) were performed by using a round bur not calibrated to the head of the scalloped implant intended to be used, because not already available at the moment of the placement of these implants. More traumatic drilling may have led to more bone loss. More precise and dedicated instruments would now be needed for the new surgical procedure.

The surgical technique presented in this study, interproximally, puts the bone level higher, with osseous falls in midfacial and midlingual positions. From a clinical stand point this means that, in the ear-

ly phase of healing, there is better inter-implant soft tissue support compared to flat platform implants. A one stage surgical approach might have probably further limited marginal bone remodelling.

When papillae are lost, regeneration may also depend on the inability of the cells present in the surrounding marginal gingiva to recapitulate the specific phenotypic properties of the interdental papilla cells (42). However, it should be emphasized that it was expected only 3,4 mm on an average of vertical distance from the crest of bone to the height of the inter-implant papilla (2).

In some clinical cases the muco-gingival junction shifted to a new more palatal position, where more keratinized tissue was present, with better esthetics of the papillae on the palatal aspect. This was due to bone reabsorption modalities and soft tissue modifications of the maxilla (43).

In the past decades, sophisticated periodontal surgical procedures (13,44-49) have obtained aesthetic but illusive (4) inter-implant papillae with pseudo-pocket formation around implants (8), especially in the interproximal areas.

Thus, in cases of optimal clinical results, crown margins equidistant from osseous structures and a 360° constant biologic width around the entire circumferences of scalloped implants, placed in combination of the above presented technique, may reduce excess of cement in the inter-implant areas as advocated by some authors (32,50), prevent pseudo-pocket formation around implants which is a risk as stated by Choquet et al. (8), and lead to better plaque control by the patient and by the hygienist, reducing the possibilities to develop periodontal disease. These findings also lead to the clinical consideration that the regeneration of a certain amount of inter-implant papilla in flat ridges, may have positive effects on speech and decreases food impaction in the posterior as well as in the anterior areas.

Conclusions

The preliminary results of this study seem to suggest that the combination of the use of adjacent scalloped implants with a novel surgical approach, even in reabsorbed ridge with flat anatomy, may reform

inter-implant bone peaks supportive for papillae and lower buccal and lingual crests and gingival margins. Further research is needed to confirm the validity of this new surgical technique for the reconstruction of the inter-implant papilla in flat ridge anatomy.

Acknowledgements

This study has been partially financed by Nobel Biocare, AB, Göteborg, Sweden.

References

- Garber DA, Salama MA, Salama H. Immediate total tooth replacement. *Comp Contin Educ Dent* 2001;22:210-218.
- Tarnow D, Elian N, Fletcher P, Froum S, Magner A, Cho S.C., Salama M, Salama H, Garber D.A. Vertical distance from the crest of bone to the height of the interproximal papilla between adjacent implants. *J Periodontol* 2003;74:1785-1788.
- Kupersmidt I, Levin L, Schwartz-Arad D. Inter-implant bone height changes in anterior maxillary immediate adjacent dental implants. *J Periodontol* 2007;78:991-996.
- Grossberg DE. Interimplant papilla reconstruction: assessment of soft tissue changes and results of 12 consecutive cases. *J Periodontol* 2001;72:958-962.
- Tarnow DP, Magner AW, Fletcher P. The effect of the distance from the contact point to the crest of bone on the presence or absence of the interproximal dental papilla. *J Periodontology* 1992;63:995-996.
- Salama H, Salama MA, Garber DA, Adar P. The interproximal height of bone: a guidepost to predictable aesthetic strategies and soft tissue contours in anterior tooth replacement. *Pract Periodontics Aesthet Dent* 1998;10(9):1131-1141.
- Grunder U. Stability of the mucosal topography around single-tooth implants and adjacent teeth: 1-year results. *Int J Periodontics Restorative Dent* 2000;20(1):11-17.
- Choquet V, Hermans M, Adriaenssens P, Daelemans P, Tarnow D, Malevez C. Clinical and radiographic evaluation of the papilla level adjacent to single-tooth dental implants. A retrospective study in the maxillary anterior region. *J Periodontol* 2001;72:1364-1371.
- Kan JYK, Rungcharassaeng K, Umezu K, Kois JC. Dimensions of peri-implant mucosa: An evaluation of maxillary anterior single implants in humans. *J Periodontol* 2003;74:557-562.
- Kois CJ. Predictable single-tooth peri-implant esthetics: Five diagnostic keys. *Compend Contin Educ Dent* 2004;25:895-896,898,900 passim; quiz 906-907.
- Henriksson K, Jemt T. Measurements of soft tissue volume in association with single-implant restorations: A 1-year comparative study after abutment connection surgery. *Clin Implant Dent Relat Res* 2004;6:181-189.
- Hermann JS, Buser D, Schenk RK, Higginbottom FL, Cochran DL. Biologic width around titanium implants. A physiologically formed and stable dimension over time. *Clin Oral Implants Res* 2000;11:1-11.
- Grunder U. The inlay-graft technique to create papillae between implants. *J Esthet Dent* 1999;5:8-11.
- Palacci P. Papilla regeneration technique. In: Palacci P, Ericsson I, Engstrand P, Rangert B, eds. *Optimal Implant Positioning and Soft Tissue Management for the Branemark System*. Chicago: Quintessence; 1995:59-70.
- Tarnow DP, Cho S.C., Wallace S.S. The effect of inter-implant distance on the height of inter-implant bone crest. *J Periodontol* 2000;71:546-549.
- Jovanovic SA. Bone rehabilitation to achieve optimal aesthetics. *Pract Periodontics Aesthet Dent* 1997;9:41-52.
- Dahlin C, Lekholm U, Linde A. Membrane induced bone augmentation at titanium implants. A report of ten fixtures followed from 1 to 3 years after loading. *Int J Periodontics Restorative Dent* 1991;1:273-281.
- Becker W, Dahlin C, Becker BE, Lekholm U, van Steenberghe D, Higuchi K, Kulteje C. The use of e-PTFE barrier membrane for bone promotion around titanium implants placed into extraction sockets: a prospective multicenter study. *Int J Oral Maxillofac Implants* 1994;9:31-40.
- Hermann JS, Buser D. Guided bone regeneration for dental implants. *Current Opinion Periodontol* 1996;3:168-177.
- Hammerle CH, Karring T. Guided bone regeneration at implant sites. *Periodontol* 2000 1998;17:151-175.
- Keller EE, Van Roekel N, Desjardins R, Tolmam D. Prosthetic surgical reconstruction of severely resorbed maxilla with iliac bone grafting and tissue integrated prosthesis. *Int J Oral Maxillofac Implants* 1986;1:101-109.
- Berglundh T, Lindhe J. Healing around implants placed in bone defects treated with Bio-Oss. *Clin Oral Impl Res* 1997;8:117-124.
- Jensen OT, Shulman LB, Block MS, Iacono VJ. Report of the sinus consensus conference of 1996. *Int J Oral Maxillofac Implants* 1998;13(Suppl):11-45.
- Chin M, Toth BA. Distraction osteogenesis in maxillofacial surgery using internal devices: Review of 5 cases. *Int J Oral Maxillofac Surg* 1996;54:45-53.
- Salama H, Salama MA. The role of orthodontic extrusive remodeling in the enhancement of soft and hard tissue profiles prior to implant placement: a systematic approach to the management of extraction site defects. *Int J Periodontics Restorative Dent* 1993;13(4):331-333.
- Van Venrooy JR, Yukna RA. Orthodontic extrusion of single-rooted teeth affected with advanced periodontal disease. *Am J Orthod* 1985;87(1):67-74.
- Pontiero R, Celenza F Jr, Ricci G, Carnevale G. Rapid extrusion with fiber resection: a combined orthodontic-

- periodontic treatment modality. *Int J Periodontics Restorative Dent* 1987;7(5):31-43.
28. Levin L, Pathael S, Dolev E, Schwartz-Arad D. Esthetic versus surgical success of a dental implant replacing a missing single anterior maxillary tooth: 1-9 years follow up. *Pract Proced Aesthet Dent* 2005;17:533-538.
 29. Denissen HW, Kalk W, Veldhuis HAH, van Waas MAJ. Anatomic consideration for preventive implantation. *Int J Oral Maxillofac Implants* 1993;8:191-196.
 30. Orenstein IH, Synan WJ, Truhlar RS, Morris HF, Ochi S. Bone quality in patients receiving endosseous dental implants. DICRG Interim Report No.1. *Implant Dent* 1994;3:90-96.
 31. Wohrle PS. Single-tooth replacement in the aesthetic zone with immediate provisionalization: fourteen consecutive case reports. *Pract Periodontics Aesthet Dent* 1998;10:1107-1114.
 32. Harvey BV. Optimizing the esthetic potential of implant restorations through the use of immediate implants with immediate provisionals. *J Periodontol* 2007;78:770-776.
 33. Schwartz-Arad D, Laviv A, Levin L. Survival of immediately provisionalized dental implants placed immediately into fresh extraction sockets. *J Periodontol* 2007;78:219-223.
 34. Wohrle PS. Nobel Perfect esthetic scalloped implant : Rationale for a new design. *Clin Implant Dent Relat Res* 2003;5 suppl.1:64-73.
 35. Lekholm U, Zarb GA. Patient selection and preparation. In: Branemark PI, Zarb GA, Albrektsson T. *Tissue-integrated prostheses*. Chicago: Quintessence;1985. p. 199-209.
 36. Base of radiographic data. General radiographic evaluation. General radiographic evaluation of NobelPerfect Implants. *European Journal for dental implantologists*. 2006 (Suppl.):20-22.
 37. Grunder U, Gracis S, Capelli M. Influence of the 3-D bone-to-implant relationship on esthetics. *Int J Periodontics Restorative Dent* 2005;25:113-119.
 38. Tolman DE. Reconstructive procedures with endosseous implants in grafted bone: a review of the literature. *Int J Oral Maxillofac Implants* 1995;10:275-294.
 39. Hermann JS, Cochran DL, Nummikoski PV, Buser D. Crestal bone changes around titanium implants. A radiographic evaluation of unloaded nonsubmerged and submerged implants in the canine mandible. *J Periodontol* 1997;68:1117-1130.
 40. Hermann JS, Buser D, Schenk RK, Cochran DL. Crestal bone changes around titanium implants. A histometric evaluation of unloaded non-submerged and submerged implants in the canine mandible. *J Periodontol* 2000;71:1412-1424.
 41. Abrahamsson I, Berglundh T, Lindhe J. The mucosal barrier following abutment dis/reconnection. An experimental study in dogs. *J Clin Periodontol* 1997;24:568-572.
 42. Csiszar A, Wiebe C, Larjava H, Hakkinen L. Distinctive molecular composition of human gingival interdental papilla. *J Periodontol* 2007;78:304-314.
 43. Misch CE, Judy KWM. Classification of partially edentulous arches for implant dentistry. *Int J Oral Implants* 1987;4(2):7-12.
 44. Sevor JJ. The use of free gingival grafts to improve the implant soft tissue interface: rationale and technique. *Pract Periodontics Aesthet Dent* 1992;4(9):59-64.
 45. Tinti C, Parma-Benfenati S. Coronally positioned palatal sliding flap. *Int J Periodontics Restorative Dent* 1995;15(3):298-310.
 46. Salama H, Salama M, Garber D, Adar P. Developing optimal peri-implant papillae within aesthetic zone: guided soft tissue augmentation. *J Esthet Dent* 1995;7(3):125-129.
 47. Adriaenssens P, Hermans M, Ingber A, Prestipino V, Daelemans P, Malevez C. Palatal sliding strip flap: soft tissue management to restore maxillary anterior aesthetics at stage 2 surgery: a clinical report. *J Oral Maxillofac Implants* 1996;11:46-54.
 48. Barone R, Clauser C, Grassi R, Merli M, Pini Prato GP. A protocol for maintaining or increasing the width of masticatory mucosa around submerged implants: a 1-year prospective study on 53 patients. *Int J Periodontics Restorative Dent* 1998;18(4):377-387.
 49. Nemcovsky CE, Artzi Z. Split palatal flap II. A surgical approach for maxillary implant uncovering in cases with reduced keratinized tissue: technique and clinical results. *Int J Periodontics Restorative Dent* 1999;19:387-393.
 50. Pauletto N, Lahiffe B, Walton J. Complication associated with excess cement around crowns on osseointegrated implants: a clinical report. *Int J Oral Maxillofac Impl* 1999;14:865-868.

Correspondence to:
 Dott. Riccardo Tizzoni
 Via San Barnaba, 30
 20122 Milan, Italy
 Tel/fax: ++39-02-551-91-681
 E-mail: tizzoni.med@libero.it